

INTERNATIONAL JOURNAL OF INSTITUTIONAL PHARMACY AND LIFE SCIENCES

Medical Sciences

Case Report.....!!!

Received: 12-03-2012; Accepted: 14-03-2012

A NASAL DERMOID SINUS CYST: AN UNUSUAL PRESENTATION, INVESTIGATION AND MANAGEMENT

Dr. Mohit Srivastava*, Dr. Sunil Bhadouriya, Dr. Rohit Saxena, Dr. Ajay Lavania

Dept. E.N.T and Head & Neck Surgery; School of Medical Science & Research; Greater Noida; U.P; India

Keywords:

Nasal dermoid sinus cyst,
congenital midline mass,
nasal dermoid, nasal sinus

For Correspondence:

Dr. Mohit Srivastava

Dept. E.N.T and Head &
Neck Surgery; School of
Medical Science &
Research; Greater Noida;
U.P; India

E-mail:

dr.mohit_srivastava@yahoo.in

ABSTRACT

Midline nasal dermoid sinus cysts are uncommon congenital lesions presenting either as cysts or sinuses resulting from aberrant embryological development. They are frequently associated with intracranial extension. Accurate diagnosis and effective treatment are essential to avoid craniofacial deformations, cyst rupture, abscess formation and infection that could cause cutaneous, ocular, or intracranial complications. Early surgical excision is recommended to prevent complications or further expansion of the cyst with associated destruction of local tissue. We report an unusual case of congenital midline nasal dermoid cysts in a 10-year-old girl presented with an area of cellulitis overlying the bridge of her nose. This had occurred following an episode of direct trauma to her nose.

CASE REPORT

A 10 year old girl presented to our outpatient department with an area of cellulitis overlying the bridge of her nose. This had occurred following an episode of direct trauma to her nose. On examination she was found to have midline punctum and hairs inferior to the area of cellulitis (fig 2). A CT Scan (fig1) showed an isodense soft tissue swelling overlying the glabella with no evidence of intracranial extension, underlying bone appear normal, bilateral orbit and globes are normal. At operation a tract was found extending from punctum to a cystic cavity overlying nasal bridge. The tract and cyst were excised carefully.

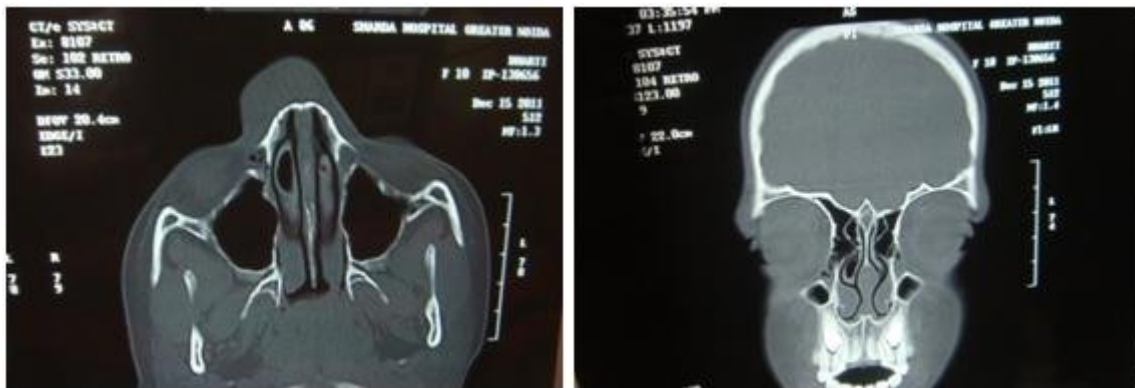


Fig.1

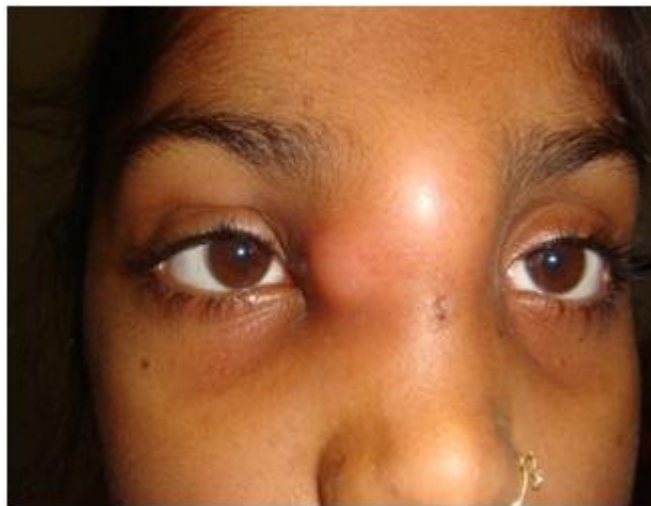

Fig-2 cellulitis associated with punctum

DISCUSSION

Nasal dermoids are rare, and often present from birth appearing on the nose as a midline mass anywhere from the glabella to columella. Nasal dermoids are the most common congenital nasal abnormality. They comprise 1-3% of all dermoids and approximately 10-12% of head and neck

dermoids. Unlike teratoma which contain all three embryonal germinal layers, congenital dermoid only contain ectodermal and mesodermal embryonic elements. Mesodermal elements, which include hair follicles, sebaceous glands, and sweat glands are found in the wall of the cyst and thus differentiate these masses from simple epidermoid cysts. Most dermoid cysts occur sporadically, although familial association have been reported. Associated abnormalities are seen in 5-41% of cases. These include aural atresia, pinna deformity, mental retardation, hydrocephalus, branchial arch sinus, cleft lip, cleft palate, hypertelorism and hemifacial microsomia¹.

Nasal dermoids occur in sporadic fashion with a slight male preponderance^(1,2). derived from epithelial cell rests enclaved in tissue during embryonal closure. Nasal dermoid sinus cysts are anomalies with an embryologic origin quite distinct from dermoids elsewhere on the face and requiring an especially careful approach to management. They are congenital lesions lined by stratified squamous epithelium. Some debate about the origin of these lesions exists, but they are thought to arise in the early embryonic period ,during closure of the anterior neuropore, during development of the frontonasal process or during closure of the fonticulus nasofrontalis^(1,2,3). In some patients, the sinus tract extends into the intracranial cavity or prenasal space; hence ,the dermal sinus or cyst may persist anywhere from foramen cecum to nasal tip. In published reports, the proportion with intracranial extension varies widely, from 6-45%^(4,5). Regardless of the embryology, the lesions may present in a variety of ways: as a cystic mass or as a sinus . Commonly, the sinus will discharge cheesy offensive material or grow abnormal hairs. Both cysts and sinuses may have a connection with an intracranial component through an abnormal foramen cecum in the anterior cranial fossa. Such connections are not usually apparent on clinical examination. The differential diagnosis needs to be carefully considered during assessment and includes ectopic neuroglia, encephaloceles, and teratomas. Common epidermoid cysts, lined by a squamous epithelium without appendages, may also uncommonly occur in the midline. A clear understanding of several features of nasal dermoid sinus cysts is critical to the diagnosis and management of this condition. First, there is a significant rate of spontaneous infection. Required prolonged intravenous antibiotic therapy to treat frontal bone osteomyelitis. Other spontaneous complications of these lesions before treatment include discharge ,aberrant hair growth, and an enlarging unsightly mass distorting nasal growth, presented with the need for

excision. The next consideration is how to best establish the true extent of the lesion so that an appropriate surgical plan is developed. The objective of imaging studies is to confirm the clinical diagnosis and to delineate any intracranial involvement if present. The complementary roles of CT and MRI appear well established in congenital midline nasal masses^(6,7,8). CT is helpful for bony anatomy, while MRI delineates a CNS connection and images soft tissues more precisely. Surgical approaches depend on the position of the cyst if it is in the lower half of the nose, an open rhinoplasty procedure is an excellent way of removing pathology and obtaining a good cosmetic result. Cyst higher up the nose may need direct excision. Extension of the sinus tract deep to the nasal bones usually necessitates a medical osteotomy to permit adequate exposure for removal. Some find a lateral rhinotomy a useful approach to expose the septum and so allow complete removal of the cyst and associated tract. Any punctum in the skin will require local excision. A careful consideration is required for intracranial extension. If this occurs a combined intracranial and extracranial procedure is recommended. If it is only suspected it is appropriate to approach the lesion via nose first and only proceed with the craniotomy if absolutely required⁽¹⁾. Extra cranial techniques, Excision and direct primary closure is the most straightforward and has the advantage of removing abnormal skin overlying a cyst or the opening of a sinus. Incisional wounds, particularly those oriented vertically, are well tolerated. Surgical scars generally settle well, and the surgeon has an opportunity to remove dysplastic or stretched skin over a sinus. Open rhinoplasty, either alone or combined with a direct excision, offers the opportunity to correct the position of the alar cartilages, which are often splayed by a lesion at the nasal tip⁽⁹⁾. A sinus tract may be followed to the nasofrontal suture via an open rhinoplasty. Endoscopic approaches are useful for superficial lesions with no extension that lie in the glabellar region. The need for an exposed scar is avoided. A craniotomy is required to remove a dermoid with intracranial extension. Various techniques have been described, removing all or part of the frontal bones via a coronal or subcranial approach.

Few details exist in the literature about the rate of recurrence and other complications after treating nasal dermoid sinus cysts. Rate of recurrence 4-12%^(1,10) Meticulous complete excision should prevent recurrence but is exceptionally difficult in the presence of infection. Few other surgical complications are superficial wound infection, and nasal airway obstruction. Although nasal dermoid sinus cysts are uncommon and complex lesions, they can be managed successfully

with careful clinical assessment, preoperative MRI and CT scans, and appropriate surgery. Tailored definitive surgery, addressing defined pathology and anatomy, allows successful treatment with a low recurrence rate and few other complications.

REFERENCES

1. Rahbar R, Shah P, Mulliken JB, The presentation and management of nasal dermoid: a 30 year experience. Archives of otolaryngology-Head&Neck surgery 2003;129:464-471.
2. Pratt LW. Midline cysts of the nasal dorsum: embryologic origin and treatment. Laryngoscope. 1965;75:968 –980.
3. Charrier J-B, Rouillon I, Roger G, Craniofacial dermoids: anembryological theory unifying nasal dermoid sinus cysts. Cleft PalateCraniofac J. 2005;42:51–57.
4. Hanikeri M, Waterhouse N, Kirkpatrick N, The management of midline transcranial nasal dermoid sinus cysts. Br J Plast Surg. 2005;58:1043–1050.
5. Denoyelle F, Ducroz V, Roger G, Nasal dermoid sinus cysts in children. Laryngoscope. 1997;107:795– 800.
6. Bloom DC, Carvalho DS, Dory C, Imaging and surgical approach of nasal dermoids. Int J Paediatr Otorhinolaryngol. 2002;62:111–122.
7. Huisman TA, Schneider JF, Martin-Fiori E, Developmental nasal midline masses in children: neuroradiological evaluation. Eur Radiol. 2004;14:243–249.
8. Schlosser RJ, Three dimensional computed tomography of congenital nasal anomalies. Int J Paediatr Otorhinolaryngol. 2002;65:125-131
9. Bilkay U, Gundogan H, Ozek C, Nasal dermoid sinus cysts and the role of open rhinoplasty. Ann Plast Surg. 2001;47:8 –14.
10. Will E. Blake, C.W. Chow, Anthony D. Holmes and John G. Meara. Nasal dermoid sinus cysts: A retrospective review and discussion of investigation and management. Ann Plast Surg. 2006;57:535-540.