

INTERNATIONAL JOURNAL OF INSTITUTIONAL PHARMACY AND LIFE SCIENCES

Medical Sciences

Original Article.....!!!

Received: 12-03-2012; Accepted: 14-03-2012

A STUDY OF CHEMICAL CAUTERIZATION OF TYMPANIC MEMBRANE PERFORATIONS BY USING TRICHLOROACETIC ACID

Dr. Sunil Bhadouriya, Dr. Mohit Srivastava*, Dr. Sushil Gaur, Dr. Ajay Lavania, Dr. Rohit Saxena

Dept. E.N.T and Head & Neck Surgery; School of Medical Science & Research; Greater Noida; U.P; India

Keywords:

TCA, Tympanic membrane perforation, Chemical cautery

For Correspondence:

Dr. Mohit Srivastava

Dept. E.N.T and Head & Neck Surgery; School of Medical Science & Research; Greater Noida; U.P; India

E-mail:

dr.mohit_srivastava@yahoo.in

ABSTRACT

To evaluate healing effect of TCA on non healing small and medium sized central tympanic membrane perforation of pars tensa , sixty patients with dry tympanic membrane perforations due to inflammatory or traumatic etiology were included in this study after treating the etiological factors like septal deviation and allergic rhinitis. Fifty percentage TCA was used to cauterize the margin. A maximum number of six applications were made, and the patients were followed up for the next 1 year. In this series of 60 patients, highest success was noted among those patients with traumatic perforation and small sized perforation while few perforations were reduced to small sized perforations which were treated by myringoplasty. An overall success rate of 68% was achieved. This method was popularized by Derlacki (1953), to close small to moderate sized tympanic membrane perforation. This is a simple and economical mode of treatment and associated with minimal complications. Although various materials have been used to modify this technique but the principle is the same.

AIM

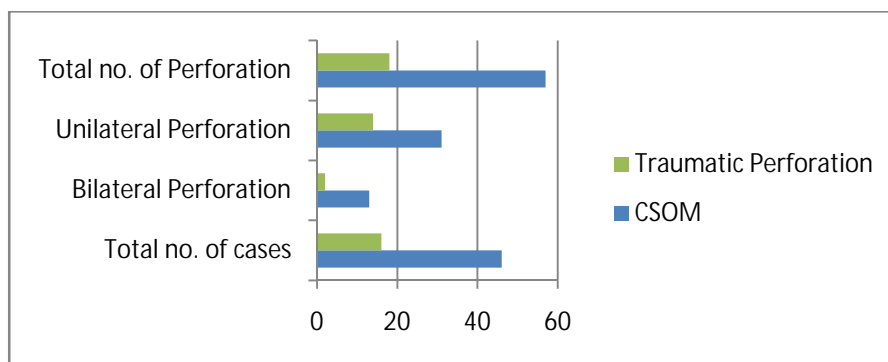
To study the effectiveness of chemical cautery with on chronic tympanic membrane perforations of the pars tensa.

INTRODUCTION

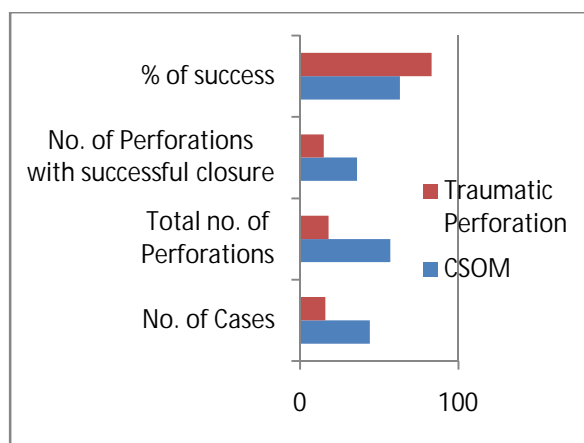
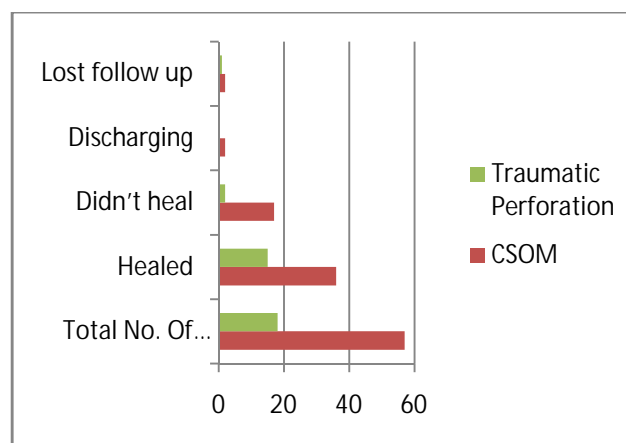
CSOM is a wide spread disease of developing countries like India especially in rural areas. it one of the commonest cause for hearing loss that mainly result due to tympanic membrane perforations. Although 88% of tympanic membrane perforations of any size heal without any interventions, the rest become chronic & require surgery. These non-healing perforations typically require tympanoplasty for closure. Medical costs associated with tympanoplasty have recently compelled investigators to search for less expensive, simple non-surgical methods. Without closure of perforation morbidity may include chronic otorrhea and cholesteatoma formation, deterioration of hearing .The purposes of closing chronic dry perforations of the tympanic membrane are to improve hearing and prevent middle ear infections. Closure isolates the middle ear from external environment and prevent contamination by exposure to pathogens and restores the vibratory area of the membrane and affords round window protection. Etiologically, tympanic membrane perforations are either due to inflammation or trauma. Many of the perforations due to otitis media heal, unless there is a coexisting eustachian tube dysfunction which is the main reason for a permanent perforation [1]. Traumatic perforations usually heal spontaneously, and it is preferable to wait for at least 3 weeks prior to any intervention. A perforated tympanic membrane results in loss of hearing due to decreased drum area and liability to recurrent infection of the middle ear mucosa. These problems limit the patient's participation in water sports, and for job recruitment in the military service and as a motor vehicle driver [4]. Closure of these perforations is gratifying to both the patient and the surgeon. The patient stands to gain as much as 25 db of hearing. In some cases, tinnitus gets relieved. Also, the patient gets a discharge free ear [5]. While surgical closure of tympanic membrane perforation still remains the choice of management, effective closure of tympanic membrane perforation can be achieved by using chemical cautery and patch technique together for small and moderate sized perforations.

MATERIALS AND METHODS

Patients attending ENT OPD in SMS&R, Sharda hospital Greater Noida from March-2010 to March 2011, who have CSOM with small to medium non healing central perforations in pars tensa and small to medium traumatic perforations in pars tensa not healing for more than one month were taken for study. Age group ranged from 14 to 70 years. Patients with both bilateral and unilateral perforations were included, making the total number of perforations for evaluation 75 (bar 1). A routine ENT examination was performed, diagnostic endoscopic study of the nose and naso-pharynx was done in all cases to rule out nasal pathology. Factors like deviated nasal septum (DNS) and allergic rhinitis were noted. Those with DNS and significant nasal block underwent septal correction and were included in the study 3 weeks after the surgery, while allergic rhinitis was controlled by antihistamines and local steroid nasal sprays. Eustachian tube patency was assessed by Valsalva's Maneuver. An Otoendoscopy / Otomicroscopy was performed to measure the size of perforation and to rule out the presence of cholesteatoma, tympanosclerosis, large perforation, subtotal perforation, marginal perforation, pars flaccid perforation. Hearing was assessed by tuning fork tests and Pure tone audiometry, with the average airborne gap ranging from 0 to 50 dB. The technique was carried out as an OPD procedure. For those who had bilateral perforations, one ear was treated first and the other ear was treated 6 weeks to 3 months later. For the initial application, 4% xylocaine was used to anaesthetize the tympanic membrane by adding a few drops into a small cotton ball and placing it into the external canal wall over the surface of the tympanic membrane for about 10 min. Under the microscope, the rim of the perforation was cauterized using a cotton tipped applicator dipped in 50% trichloroacetic acid until a white cauterized margin 0.5mm in width is created. and the excess of the chemical was drained using a dry cotton swab. Care was taken not to scar the promontory. Once the blanching of the rim was completed, a small sterile, thin paper patch moistened with antibiotic drop was placed as a patch over the perforation. Repetition of the cautery at weekly intervals is done, many of them requiring more than one application and the technique was repeated for a maximum of six times. After the first application, an antibiotic was given for 1 week, and Neosporin with hydrocortisone ear drops were instilled for 3 weeks. During follow up an Otoscopic examination, an Oto endoscopy and a PTA will be performed to assess perforation size and improvement in hearing.

**Figure 1****RESULT**

Total 60 patients (75 perforations) were treated . This included unilateral central perforation of the tympanic membrane in fourty cases, bilateral central perforation of tympanic membrane in fifteen cases, post myringoplasty residual and recurrent perforation in five cases due to coryza in the same patients. Successful closure of the central perforation was noted in average 3.6 applications(Figure4). A maximum of six applications were done before healing was noticed in two patients and a minimum of one application done in one patient. Out of 75 perforations, 51 healed , 19 did not heal and underwent for myringoplasty later, 2 started discharging and 3 cannot be commented as patient was lost for follow up (Figure 3). This clinical study showing application of trichloroacetic acid for treatment of small and medium sized Central perforation of tympanic membrane(4mm) and proves to have a beneficial effect in healing in selected patients. The smaller perforations requiring fewer number of applications .An overall success rate of 68% was achieved in this study(Figure 2).

**Figure 2****Figure 3**

No.of TCA applications for closure of tympanic membrane perforation	No. of perforations	Total average
1	1	3.6
2	15	
3	24	
4	26	
5	5	
6	2	

Table 1

Discussion: The Tympanic Membrane (TM) plays a significant role in the physiology of hearing as well as in the pathophysiology of chronic inflammatory middle ear diseases. The tympanic membrane perforations significantly impair the quality of life for millions of patients¹.

The active chronic otitis media without cholesteatoma, incidence of this condition varies widely by geography, race, and genetic predisposition, as well as socioeconomic factors. Studies in the Caucasian population show the incidence to be approximately 2%². The incidence of traumatic perforations of the tympanic membrane has been estimated at 8.6 per 1,000 persons³. Three types of traumatic perforations can occur: penetrating, blunt, and iatrogenic. It is important to keep in mind that inner ear injury may accompany acute traumatic perforations, a possibility that should be evaluated by careful questioning.

From the seventeenth to the nineteenth centuries, several attempts at closing tympanic membrane perforations using prosthetic materials were made. The first published report to close the tympanic membrane perforation was in 1640 by Marcus Banzer who inserted a small ivory tube covered with pig's bladder as a lateral graft⁴. Yearsley, in 1841, applied a ball of cotton wool moistened with glycerin against a TM perforation⁵. In 1853, Toynbee placed a rubber disk attached to a silver wire over the TM and reported significant hearing improvement⁶. The use of cauterizing agents to promote healing of tympanic membrane perforations was introduced by Roosa in 1876, who used the application of silver nitrate to the rim of a perforation⁷. The use of trichloroacetic acid was first advocated in 1895 by Okuneff. Blake covered perforations with paper patches in 1887. It was not until Joynt combined the cautery and paper patch techniques that closure results improved⁸, forming the basis of the modern-day use of the paper patch technique as popularized by Derlacki⁹.

A simple perforation of the tympanic membrane, with no additional lesion of the middle ear transformer mechanism, has two different effects on the hearing. First, there is the diminished surface area of tympanic membrane on which sound pressure is exerted, resulting in dampened ossicular chain excursion. For a small (1-mm) perforation, Békésy found that the effect on ossicular motion is confined to sounds below 400 Hz and is 12 dB at 100 Hz, 29 dB at 50 Hz, and 48 dB at 10 Hz¹⁰. The larger the perforation, the greater the loss of surface area on which sound pressure can act, with the additional factor that sound pressure entering the middle ear through the perforation can act on the posterior surface of the tympanic membrane against the sound pressure on the outer surface. In addition, the site of the perforation influences the degree of hearing loss; posterior perforations produce more severe hearing losses¹¹. A second effect of a simple perforation on hearing results from sound reaching the round window directly without the dampening and phase-changing effect of an intact tympanic membrane. Moreover, as the size of the tympanic membrane remnant decreases, the hydraulic advantage produced by a large tympanic membrane on a small oval window disappears, so that sound reaches both windows with more nearly equal force and at nearly the same time. The resultant cancellation of vibratory movement of the cochlear fluid column produces the maximum hearing loss observed in simple perforation, as much as 45 dB for the speech frequencies¹². In general, the larger the perforation, the greater the hearing impairment, but this relationship is neither constant nor consistent in clinical practice; perforations seemingly identical in size and location produce different degrees of hearing loss¹³.

A tympanic membrane perforation causes conductive hearing loss due to loss of ossicular coupling which is again due to loss of sound pressure difference across the tympanic membrane which provides the primary drive to the motion of the drum and ossicles. In addition, perforation causes a loss that depends on frequency, perforation size and middle ear space. Perforation induced losses are greatest at lowest frequencies. The volume of middle ear space also affects hearing. Smaller volume results in larger airborne gap. For a given sound pressure in the ear canal and a given perforation, the resulting sound pressure within the middle ear cavity is inversely proportional to the middle ear volume. So the transtympanic sound pressure difference will be smaller with smaller middle ear volumes. Identical perforations in two different ears have conductive losses that can differ by up to 20–30 db if the middle ear space volumes differ¹⁴. The

size of the perforation is more important in determining the hearing loss than its location¹⁴. The tendency of even very large perforation of the tympanic membrane to heal spontaneously was noted as early in 1876 by Roosa⁷. A large perforation of the tympanic membrane heals often into a thin atrophic scar which is devoid of the middle fibrous elements that provide structural support, having only an outer epidermis and inner mucosal layer. Although such a tympanic membrane is adequate for the purposes of sound conduction, it is vulnerable to repeated perforation by infection or eustachian tube dysfunction. The principle of closure by promotion of healing of the tympanic membrane involves inducing the fibrous layer to close the perforation prior to epithelial closure, restoring the normal anatomy of the tympanic membrane. An adequate trial of closure by acid cautery on several occasions, with or without marginal eversion, is an option for small and medium-sized central perforations before resorting to myringoplasty⁹.

Histo pathological study of a newly formed perforation shows proliferation of squamous epithelium within 12 hours at the edge of the perforation, granulation formation within 36 hours¹⁵, while the inner mucosa of the membrane takes several days to regenerate. As long as there is a suitably flat surface, stratified squamous epithelium grows at the rate of 1 mm a day¹⁶. Histopathologic examination of permanent perforations showed that stratified squamous epithelium grows medially over the edge of the perforation with no raw surface¹⁷, which appears to arrest the subsequent closure of the perforation. Removal of this medialized epithelium forms the basis of some of the treatments for tympanic membrane perforation. The cytokines implicated in this arrest of healing may be multiple, but transforming growth factor- β 1 (TGF- β 1) is found at the border of the chronic perforation and may mediate the arrest of healing¹⁸. The principle of chemical cauterization is, it breaks up fibrosis, promotes granulation and new tissue formation at the margin of the perforation. The patch acts as a splint to bridge the margins of the perforation and give flat surface. Few principles have to be kept in mind when promoting healing of perforation by acid cautery of the rim¹⁹, The outer squamous epithelium that has grown inward across the edges must be destroyed repeatedly, to permit fibroblastic proliferation of the fibrous layer, the rim of the perforation should be kept moist as drying immediately kills the young fibroblasts, hyperemia stimulates fibroblastic proliferation and should be induced by mild irritation. Simple closure should be undertaken only for inactive central perforations with good eustachian tube patency. If the tube cannot be inflated, closure

would result in secretory otitis media with no gain in hearing. Closure is more likely when the perforation is small or medium in size and involves no more than 65% of the pars tensa.

Myringoplasty recommended for perforations involving more than 65% of the pars tensa, for narrow external canal preventing a view of the anterior edge of the perforation and for patients who refuse to come for repeated follow up¹⁹. In the literature, various methods have been used other than chemical cautery, in the non surgical closure of perforations, like the irritant oil method, fibrin glue²⁰, fat plug²¹ carbon dioxide laser trimming of the margins before applying paper patch etc.²². Different patching materials have also been used. Wright (1956) used cotton patch with neomycin ear drops, while Mitchell (1958) used sterispon gelatin sponge soaked in patient's own blood. Juers reported an 88% success with an average of 3.7 applications. He had further everted the margins of the perforation under the operating microscope, whereas Derlacki who reported 75% success in office treatment at biweekly intervals had used cautery alone. Dunlop had a 100% success with 3–33 treatment at biweekly intervals²³. T.santhi reported 73.75% success rate²⁴. In this study, we noted highest success among patients with traumatic perforations. present study gave an overall success rate of 68%, which is comparable with the previous studies documented in the literature.

Conclusion: This procedure was found to be a promising office-based technique for the closure of chronic tympanic membrane perforations. This procedure of chemical cauterization and patching used today demonstrates the improvement in hearing likely to be achieved by tympanoplasty. This OPD procedure is relatively easy, simple, safe, and economical. Surgical complications of middle ear surgery can be avoided by this technique. This procedure may be safely tried among those with systemic medical conditions and in whom surgical intervention is contraindicated. Small perforation and traumatic perforation, had a better healing rate in this study. Disadvantage of this procedure is that multiple sitting is required. it is an effective means of tympanic membrane closure in selected patients, thereby reducing the surgical waiting list and saving time and money for the patient.

REFERENCES

1. Anisur Rahman. Healing of tympanic membrane perforation : an experimental study by. From Karolinska Institute And University Hospital Stockhole Sweden 2007, ISBN 978-91-7357-2439.

2. Browning GG, Gatehouse S. The prevalence of middle ear disease in the adult British population. *Clin Otolaryngol* 1992;17:317–21.
3. Griffin WL, Jr. A retrospective study of traumatic tympanic membrane perforations in a clinical practice. *Laryngoscope* 1979;89:261–82.
4. Banzer, M. (1640) *Disputatio de auditione laesa* (Disertation on deafness)
5. Yearsley J. *Deafness practically illustrated*. London: Churchill & Sons; 1863.
6. Toynbee J. *On the use of an artificial membrana tympani in cases of deafness dependent upon perforations or destruction of the natural organ*. London: J. Churchill & Sons; 1853.
7. Roosa DB. *Diseases of the ear*. New York: William Wood & Co.; 1876.
8. Joynt JA. Repair of drum. *Iowa Med Soc* 1919;9:51.
9. Derlacki EL. Repair of central perforations of tympanic membrane. *Arch Otolaryngol* 1953;58:405.
10. Békésy G von. *Über die mechanisch-akustischen Vorgänge beim Hören*. *Acta Otolaryngol (Stockh)* 1939;27:281–388.
11. Yung MW. Myringoplasty: hearing gain in relation to perforation site. *J Laryngol Otol* 1983;97:11–7.
12. Derlacki EL. Residual perforations after tympanoplasty: office technique for closure. *Otolaryngol Clin North Am* 1982;15:861:7.
13. Payne MC, Githler FJ. Effects of perforations of the tympanic membrane on cochlear potentials. *Arch Otolaryngol* 1951;54:666.
14. Gulya AJ, Glasscock ME (2003) *Glasscock, Shambaugh surgery of the ear*, 5th edn. BC Decker Inc, Spain, pp 400–420
15. Taylor M. McMinn RM. Healing of experimental perforations of the tympanic membrane. *J Laryngol Otol* 1965;79:148.
16. Gladstone HB, Jackler RK, Varav K. Tympanic membrane wound healing. An overview. *Otolaryngol Clin North Am* 1995;28:913–32.
17. Yamashita T. Histology of the tympanic perforation and the replacement membrane. *Acta Otolaryngol (Stockh)* 1985;100:66–71.
18. Somers T, Goovaerts G, Schelfhout L, et al. Growth factors in tympanic membrane perforations. *Am J Otol* 1998;19:428–34.

19. Shambaugh GE (1967) Glasscock, Shambaugh surgery of the ear, 2nd edn. W.B. Saunders Company, Philadelphia, pp 429–437
20. Dorsun E (2008) Comparison of paper-patch, fat, and perichondrium myringoplasty in repair of small tympanic membrane perforations. *Otolaryngol Head Neck Surg* 138:353–356
21. Upal KS (1997) Closure of tympanic membrane perforation by chemical cautery. *IJOL HNS* 49:151-153
22. Lee SH, Lee KC et al (2008) Paper patch myringoplasty with carbon dioxide laser for chronic tympanic membrane perforations. *Eur Arch Otorhinolaryngol* 265:1161–1164
23. Goldman NC (2007) Chemical closure of chronic tympanic membrane perforation. *ANZ J Surg* 77:850–851
24. T.Santhi.K.V.Rajan(2011)A study of closure of tympanic membrane perforations by chemical cauterization. *Indian J Otolaryngol Head Neck Surg*.